

Fractionated Stereotactic Radiotherapy for the Management of Optic Nerve Sheath Meningiomas



R. B. Den¹, S. Tjoumakaris², M. Werner-Wasik¹, J. Evans², W. J. Curran¹, D. W. Andrews²

Thomas Jefferson University Hospital, Department of Radiation Oncology¹, Department of Neurosurgery², Philadelphia, PA

PURPOSE

The management of meningiomas involving the optic nerve sheath presents unique treatment challenges due to their critical location and progressive visual deterioration. Surgery has traditionally been the mainstay of treatment however it is typically a blinding procedure. We assessed the efficacy both in terms of local control and preservation of visual acuity as well as safety of fractionated stereotactic radiotherapy (FSR) for the management of optic nerve sheath meningiomas (ONSM).

METHODS

We retrospectively analyzed 58 patients with ONSM treated between 1996-2006 on a dedicated 6 MV stereotactic LINAC. All cases were discussed in a multidisciplinary radiosurgery tumor board. We reviewed patient charts for RT technical information and for treatment outcomes, including local control (LC), visual acuity, and acute and late toxicity related to treatment. Patients were evaluated clinically by neurosurgery, radiation oncology and ophthalmology. Patients had visual acuity and visual fields assessed both at presentation and follow up; radiographically LC was measured by magnetic resonance imaging.

RESULTS

Figure 1: Patient Characteristics

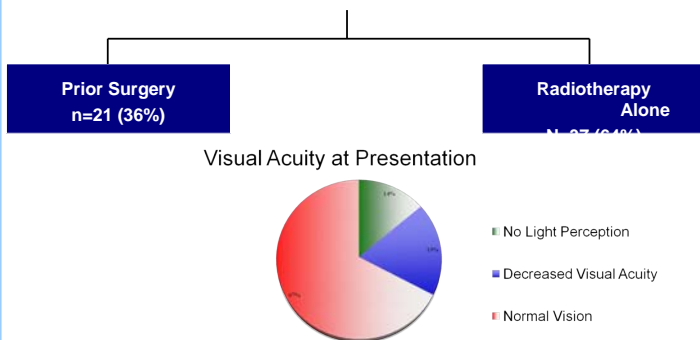


Figure 2: Sample DVH

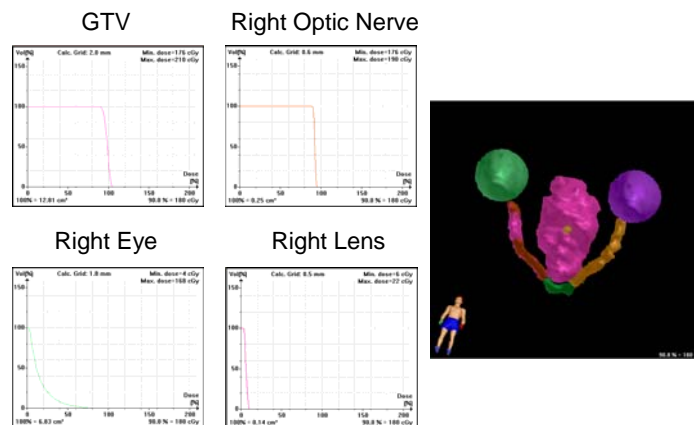
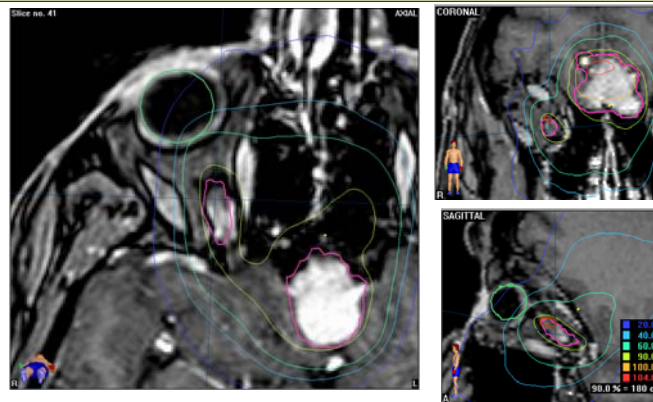
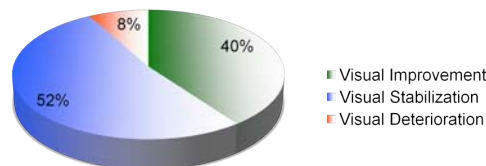


Figure 3: Representative LINAC Stereotactic Radiotherapy Plan



Post treatment Vision & Toxicity



- One patient developed an acute transient treatment related optic neuritis which resolved with steroids.
- One patient developed central retinal venous occlusion.
- One patient developed tumor progression.
- There were no other RTOG Grade 3 or higher late complications.

Figure 4: Pre- & Post-treatment Perimetry




Figure A. Left Image pretreatment perimetry revealed full visual field in right eye and post treatment course was notable for stable visual acuity and full visual field at 4 year follow up. Figure B. Left image pretreatment findings included arcuate field cuts in the right eye and post treatment course was notable for subjective visual improvement in the right eye with improvement in visual field at year and a half follow-up

DISCUSSION / CONCLUSION

This is the largest U.S. cohort of patients with optic nerve sheath meningiomas treated with fractionated stereotactic radiotherapy. We found that this modality provided excellent local control and stabilization of vision with low morbidity and no mortality and 40% of patients exhibiting improvement in vision. This data in conjunction with other studies in the literature suggest that FSR is the standard of care for patients with ONSM.

For more information please contact:
Robert Den - robert.den@jeffersonhospital.org
David Andrews - david.andrews@jefferson.edu